

Effects on Oral Soft Tissue Produced by a Diode Laser In Vitro

K. Goharkhay, MD, DMD,¹ A. Moritz, MD, DMD,^{1*} P. Wilder-Smith, MD, DMD,²
U. Schoop, MD, DMD,¹ W. Kluger, MD,¹ S. Jakolitsch, MD,¹ and W. Sperr, MD, DMD¹

¹Department of Conservative Dentistry, Dental School, University of Vienna,
A-1090 Vienna, Austria

²Beckman Laser Institute and Medical Clinic, University of California, Irvine,
Irvine, California 92697

Background and Objectives: This investigation determined incision characteristics and soft-tissue damage resulting from standardized incisions using a wide range of laser modes and parameters of a diode laser at 810 nm.

Study Design/Materials and Methods: Histologic examinations were performed to verify vertical and horizontal tissue damage as well as incision depth and width.

Results: Incision depth and width correlated strongly with average powers, but not with laser parameters or the used tips. No laser damage was visible to the naked eye in the bone underlying the incisions in the range between 0.5–4.5 W.

Conclusion: The remarkable cutting ability and the tolerable damage zone clearly show that the diode laser is a very effective and, because of its excellent coagulation ability, useful alternative in soft-tissue surgery of the oral cavity. *Lasers Surg. Med.* 25:401–406, 1999.

© 1999 Wiley-Liss, Inc.

Key words: incision depth; mucosa; collateral tissue damage

INTRODUCTION

The scalpel and the conventional electrosurgery unit are the instruments of choice for soft-tissue surgery. In addition, lasers are an alternative to conventional surgical systems. Scalpels have been used for many years because of their ease of use, accuracy, and minimal damage to the surrounding tissue. On the other hand, scalpels cannot provide the hemostasis that is helpful for use on highly vascular tissue [1].

One characteristic difference between a laser and a scalpel cut is the generation of a coagulated tissue layer along the walls of the laser incision [2]. All laser-tissue interactions produce some degree of tissue vaporization and a surrounding zone of thermal necrosis [3]. This zone of thermal damage should ideally be kept to a minimum, as it may impede wound healing and graft take, and reduce tensile strength [2]. Clinical experience suggests some advantages for laser over scalpel surgical procedures of the oral tissues. Advan-

tages of this tool include greater precision, a relatively bloodless surgical and postsurgical course, sterilization of the surgical area, minimal swelling and scarring, coagulation, vaporization, and cutting, minimal or no suturing, and much less or no postsurgical pain [4–6]. Research has consistently demonstrated that laser surgery can be performed safely by using parameters which protect underlying bone and tooth structures [7]. The factors that determine the initial tissue effect include the laser wavelength, laser power, the available laser waveform (continuous wave, chopped, and pulsed beams), tissue optical properties, and tissue thermal properties [8]. At this time, oral laser applications do not replace the majority of

*Correspondence to: Prof. A. Moritz, Department of Conservative Dentistry, Dental School, University of Vienna, Wahringerstr. 25a, A-1090 Vienna, Austria.

Accepted 25 May 1999

traditional scalpel procedures or the high-speed drill. Certain lasers are ideal for specific oral procedures, but lasers cannot provide the same efficiency and efficacy as a scalpel for many different oral procedures [4]. Electrosurgery units produce adequate hemostasis but result in greater thermal injury and also have the disadvantage of causing muscle fasciculations. Reports suggest that healing is delayed for electrosurgery wounds when compared with scalpel wounds [1]. The thermal and histologic events resulting from soft-tissue incision with different CO₂ lasers have already been determined [2]. These examinations showed that incision depths correlate positively with the average power [9–11]. Diode lasers have been used successfully for conditioning enamel and dentin surfaces. Furthermore, the diode laser reveals a bactericidal effect and helps to reduce inflammation in the root canal and in the periodontal pocket in addition to scaling [12–14].

The aim of this study was to determine incision characteristics and soft-tissue damage resulting from standardized incisions using a wide range of laser modes and parameters of a diode laser at 810 nm.

MATERIALS AND METHODS

For this investigation, 17 fresh pig mandibles were used no later than 6 hours after the animals' death. Immediately after death, the mandibles were cooled until 1 hour before use and then returned to room temperature. Six standardized incisions per laser parameter combination, 3 cm in length, were made in the oral mucosa parallel to the border of the mandible. Three incisions per parameter were positioned 5 mm below the gingival margin, and three in the thicker soft tissue 5 mm from the lower border of the mandible. The average thickness of these tissues was 0.8–2 mm. A total of 198 incisions was made. The incisions were performed in the anterior, middle, and posterior third of the mandible. The incision length was standardized, with a template positioned 3 mm below the planned incision site during the performance of each incision. The laser handpiece was attached to a motorized device to standardize the incision and to control movements. Radiation was applied by the handpiece at a speed of 10 mm/second and was timed with a stopwatch. This experimental model has been used for many years in standardized studies [2,3,15].

Treatment was carried out with 33 different

settings of the Dentek LD 15 diode laser (Dentek Austria GMBH, Gasselberg 53–54, A-8564 Gaisfeld, Austria). This laser has a wavelength of 810 nm. The laser output power ranges from 0.5–15 W. A pulse rate of 2–32 msec in pulsed mode and a frequency of 1.5–250 Hz can be used. The laser can also be operated in continuous wave mode. The target beam is generated by a helium-neon laser (533 nm, 1 mW).

The application occurred with a 200- or 400- μ m tip. Not only continuous wave (cw), but also pulsed modes with a frequency of 25 Hz and 30-msec pulse width, and 50 Hz and 10 msec, were used. The mentioned output powers do not correspond to the output powers described on the laser instrument, but were measured directly at the outflow of radiation with a wattmeter. The 400- μ m tip was used in a measured range of 0.5–4.5 W, whereas a maximum of 2 W could be achieved for the thinner 200- μ m tip.

Immediately after irradiation, incisions were dissected out with a margin exceeding 5 mm and divided with a scalpel. The bone underlying each incision was marked, labeled, and photographed. The chief evaluation factor for bone was charring, which was selected as a gross indicator of significant laser-induced thermal damage.

The soft-tissue samples were fixed directly in 10% neutral-buffered formalin for 15 days and were dehydrated for 8 days in a rising alcohol series. After treatment with terpineol and toluol for 10 days, the specimens were embedded in paraffin for another 8 days. A total of 198 wax blocks was prepared, and 6- μ m sections were cut routinely with the microtome and stained with Serius red. Measurements were made from 15 slides per parameter and incision site. A photographic record of the results was made. Incision depth and width, as well as depth and width of adjacent tissue damage, were determined. A typical slide with measurement locations is shown in Figure 1.

RESULTS

Mean incision depths and widths, as well as mean collateral vertical and horizontal damage measurements and standard deviations, are presented in Tables 1 and 2. Mean incision depths using cw and a 400- μ m tip measured from 217.5–647.5 μ m, and mean incision widths from 78.8–357.5 μ m. Using the 200- μ m tip, mean incision depths of 405–605 μ m and mean widths of 87.6–278.3 μ m were measured. In the 50-Hz/10-msec pulsed mode, mean depths ranged from 295–737.5 μ m. Mean widths of 162.5–400 μ m were

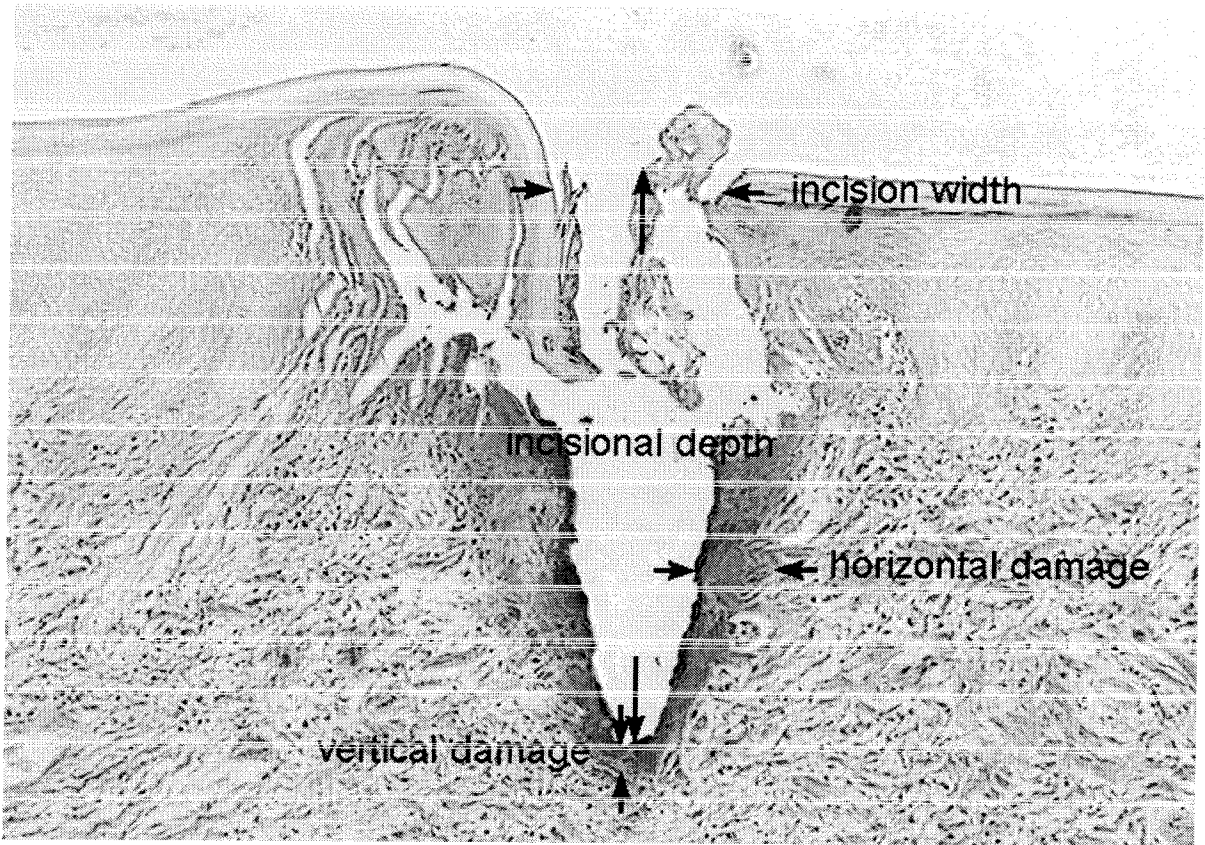


Fig. 1. Incisional and collateral effects of diode laser in oral soft tissue.

measured for the 400- μm tip, while mean incision depths from 240–614.3 μm and mean widths from 103.8–210.3 μm were determined for the 200- μm tip. The 25-Hz/30 msec pulsed mode revealed mean depths from 298.5–527 μm and mean widths from 138.8–377.5 μm for the thicker tip, and mean incision depths from 201.6–345 μm and widths from 115.2–244.3 μm for the thinner tip.

Mean vertical damage measured from 22.5–85.3 μm and mean horizontal damage from 28.3–98 μm , irrespective of the laser parameters and tips used.

The depth and width of incision correlated strongly and positively with average powers, but not with laser parameters or the tips used.

To the naked eye, no laser damage was visible in the bone underlying the incisions, either in the thicker soft tissue or in the thinner soft tissue.

DISCUSSION

Histologic events resulting from soft-tissue incisions with different CO_2 lasers have already

been determined. Histologic effects are related to the parameters used and the beam characteristics rather than wavelength; greater damage to the collateral tissues has been observed with the use of the constant wave mode. This effect enhances thermocoagulation to achieve hemostasis and provide a bloodless surgical field. The desired results with the least risk of unwanted thermal damage can be achieved with very short pulses at the highest power density for the shortest time possible [2]. The extent of collateral thermal effects is smaller by a factor of about 2–3 for the superpulse mode in comparison to the cw mode [16,17]. A wide range of clinical effects can be achieved consistently and predictably in soft tissue, depending on the parameter configuration selected. The use of higher average powers correlates with increasing depths of incision. Incision width and collateral damage are the results of complex interactions between the different laser parameter variables, as mentioned. Incision shape and width are strongly mode-dependent. The cw mode produces

TABLE 1. Incisional and Collateral Effects of 400- μ m Tip*

Average power (W)	Pulse width (msec)	Pulse repetition (Hz)	Mean \pm SD incision depth in μ m (n)	Mean \pm SD incision width in μ m (n)	Mean \pm SD vertical damage in μ m (n)	Mean \pm SD horizontal damage in μ m (n)
0.5		cw	217.5 \pm 12.6 (15)	78.8 \pm 19.3 (15)	30 \pm 4.0 (15)	29.8 \pm 1.3 (15)
1		cw	230 \pm 18.7 (15)	119.3 \pm 8.7 (15)	22.5 \pm 6.5 (15)	37.5 \pm 6.5 (15)
1.5		cw	272.3 \pm 12.3 (15)	175 \pm 23.8 (15)	44.5 \pm 5.3 (15)	56.3 \pm 25 (15)
2		cw	302.5 \pm 22.2 (15)	205 \pm 17.3 (15)	40 \pm 8.2 (15)	77.5 \pm 2.1 (15)
2.5		cw	421.3 \pm 19.3 (15)	277.5 \pm 20.6 (15)	48.8 \pm 4.8 (15)	76.8 \pm 4.6 (15)
3.5		cw	593 \pm 9.5 (15)	300 \pm 7.1 (15)	46.3 \pm 5.1 (15)	73.3 \pm 11.6 (15)
4.5		cw	647.5 \pm 9.6 (15)	357.5 \pm 30.3 (15)	55 \pm 4.1 (15)	98 \pm 33.4 (15)
0.5	30	25	298.5 \pm 11.5 (15)	138.8 \pm 8.5 (15)	35 \pm 12.9 (15)	40 \pm 4.1 (15)
1	30	25	380 \pm 40.8 (15)	162.5 \pm 6.5 (15)	28.3 \pm 2.4 (15)	51.8 \pm 16 (15)
1.5	30	25	416.3 \pm 13.8 (15)	218.8 \pm 1.7 (15)	23.3 \pm 5.4 (15)	55.75 \pm 4.3 (15)
2	30	25	488.7 \pm 12.6 (15)	275.7 \pm 14.1 (15)	48.6 \pm 7.7 (15)	49 \pm 2.6 (15)
2.5	30	25	476.3 \pm 18 (15)	371.3 \pm 8.5 (15)	44.9 \pm 10.2 (15)	66.7 \pm 5.8 (15)
3.5	30	25	497 \pm 12.6 (15)	367 \pm 15 (15)	57.5 \pm 6.5 (15)	72.5 \pm 32 (15)
4.5	30	25	527 \pm 22.2 (15)	377.5 \pm 45.7 (15)	56.3 \pm 4.8 (15)	97.5 \pm 12.6 (15)
0.5	10	50	295 \pm 13 (15)	213.75 \pm 4.8 (15)	28.8 \pm 3 (15)	37.5 \pm 2.9 (15)
1	10	50	477.5 \pm 9.6 (15)	162.5 \pm 8.7 (15)	23.8 \pm 4.8 (15)	35 \pm 5.8 (15)
1.5	10	50	492.5 \pm 6.5 (15)	248.8 \pm 9.8 (15)	43.8 \pm 4.8 (15)	63.3 \pm 7 (15)
2	10	50	590 \pm 8.2 (15)	304.8 \pm 12.7 (15)	34.5 \pm 5.3 (15)	55 \pm 5.8 (15)
2.5	10	50	587 \pm 20.6 (15)	372.7 \pm 20.2 (15)	75 \pm 20.4 (15)	78.8 \pm 29.5 (15)
3.5	10	50	707.5 \pm 17.1 (15)	400 \pm 8.2 (15)	70 \pm 21.6 (15)	65 \pm 12.9 (15)
4.5	10	50	737.5 \pm 9.6 (15)	377.5 \pm 48 (15)	80 \pm 35.8 (15)	87.2 \pm 8.6 (15)

*SD, standard deviation.

TABLE 2. Incisional and Collateral Effects of 200- μ m Tip*

Average power (W)	Pulse width (msec)	Pulse repetition (Hz)	Mean \pm SD incision depth in μ m (n)	Mean \pm SD incision width in μ m (n)	Mean \pm SD vertical damage in μ m (n)	Mean \pm SD horizontal damage in μ m (n)
0.5		cw	405 \pm 20.8 (15)	98.3 \pm 9.3 (15)	52 \pm 4.3 (15)	53.9 \pm 8.1 (15)
1		cw	475.7 \pm 8.9 (15)	87.6 \pm 13.7 (15)	47.8 \pm 4.7 (15)	55.5 \pm 11.3 (15)
1.5		cw	520.5 \pm 29.7 (15)	138.3 \pm 9.3 (15)	60.3 \pm 5.6 (15)	59.8 \pm 7.5 (15)
2		cw	605 \pm 16.38 (15)	278.3 \pm 19.8 (15)	59.5 \pm 8.6 (15)	62 \pm 9.4 (15)
0.5	30	25	201.6 \pm 6.3 (15)	195.8 \pm 5.7 (15)	29.3 \pm 3.3 (15)	28.3 \pm 3.3 (15)
1	30	25	307.5 \pm 9.6 (15)	115.2 \pm 11.1 (15)	37.5 \pm 6.5 (15)	31.5 \pm 5 (15)
1.5	30	25	262.5 \pm 6.5 (15)	204.3 \pm 9.9 (15)	60.3 \pm 5.6 (15)	48.8 \pm 3 (15)
2	30	25	345 \pm 12.9 (15)	244.3 \pm 8.3 (15)	58.4 \pm 11.6 (15)	42.7 \pm 7.9 (15)
0.5	10	50	240 \pm 18.3 (15)	103.8 \pm 11.1 (15)	38.8 \pm 6.3 (15)	49.5 \pm 4.2 (15)
1	10	50	306.4 \pm 7.7 (15)	111.8 \pm 12.5 (15)	85.3 \pm 8.5 (15)	60.6 \pm 8.2 (15)
1.5	10	50	566.3 \pm 12.5 (15)	157.8 \pm 13.3 (15)	81.4 \pm 9 (15)	53.1 \pm 8.5 (15)
2	10	50	614.3 \pm 11.8 (15)	210.3 \pm 7.6 (15)	75.9 \pm 6.9 (15)	56.2 \pm 10.5 (15)

*SD, standard deviation.

relatively wide, straight-sided incisions. Therefore, this mode can cut or ablate large amounts of tissue. Comparable incisions in depth can be achieved equally quickly and efficiently at lower average powers with the superpulse mode [3].

Of the clinically common dental lasers, the CO₂ laser usually produces narrower zones of damage in soft tissues than does the Nd:YAG laser because of the greater absorption of the CO₂ wavelength by soft tissues [18–20]. The average zone of damage caused by CO₂ lasers after laser incision in soft tissues is less than 0.6 mm [16,18, 21–23]. This finding is directly relevant to clinical

dentistry because of concerns regarding possible damage to neighboring structures, such as teeth or bone, during soft-tissue laser surgery. Comparisons of Nd:YAG and diode laser show that, when used in contact mode, these two lasers produce similar extents of tissue vaporization and zones of thermal necrosis [24]. With 10–12 W, values of 0.625 and 0.79, respectively, and 0.48 and 0.9 mm, respectively, are obtained with diode and Nd:YAG lasers [25,26]. Although the extent of tissue vaporization at low powers is less for the diode laser, these differences are not apparent at higher laser powers and energies that can be

clinically applied with commercially available units [24].

However, the radiation of a diode laser shows a greater absorption and a smaller penetration depth than that of a Nd:YAG laser, especially in blood-rich tissue. The wavelength of the diode laser is considerably more absorbed due to hemoglobin than that of the Nd:YAG laser. This causes not only a better incision performance but also an excellent coagulation of tissue [27]. The thickness of the charring layer and the coagulation layer, and incision depth, are similar for the diode laser and the Nd:YAG laser with the same laser settings [25].

Advantages of the diode laser seen in our clinical routine are that it requires no anesthetics and that the wounds heal softly. Moreover, its simple use allows very good modeling of the gingiva.

Favorable results in other dental areas encouraged us to determine the surgical effects on soft tissue produced by a diode laser, using two different tips in continuous wave mode and two pulsed modes. According to our results, the incision depth correlates strongly and positively with the average power, whereas incision shape and width depend neither on the mode used, nor on the fiber. These results confirm the findings reported by Judy et al. [25], who investigated the Nd:YAG laser. A possible explanation may be the chopped operating mode of the diode laser.

The horizontal and vertical damage zone depends neither on the average power, nor on the mode used or fiber tip. When compared with the CO₂ laser, one characteristic difference from the diode laser can be found, namely that no trend of greater damage to lateral tissues with the constant wave mode at higher power levels can be observed. Also, no charring of bone underlying 0.8-mm-thick soft tissue was observed with the continuous wave mode, or with the pulsed mode at an average power of 4.5 W. Several authors have reported that the use of the CO₂ laser can result in possible damage to the underlying bone around teeth when cutting tissues with either pulsed or continuous wave CO₂ lasers [2,3,28]. Clayman et al. [29] described minimal damage to the bone under gingiva treated with a CO₂ laser, but the gingiva healed well, although over a longer period of time. It is possible that the laser wavelength is transmitted through the surface layer of the bone into the inner cancellous tissue. Simple observation of the surface does not preclude inner damage. However, in this study, low-

power settings were used, so that the possibility of damage was extremely remote.

Blood circulation acts as a potential, not very significant coolant. One typical example of heat convection in tissue is heat transfer due to blood flow. Due to the low perfusion of most tissues, however, heat convection is negligible in a first approximation. Only during long exposures does it play a significant role [30]. Certainly an adverse cellular response will over time change the histological picture of the tissues affected. Yet the focus of this study was on the measurement of direct thermal damage, not on tissue response to laser irradiation.

Contrary to other investigations [3,7], deeper incisions could be achieved with the diode laser than were achieved by other authors with the CO₂ or Nd:YAG laser at the same power setting, even with fewer movements of the delivery system. Even the horizontal and vertical zones of thermal damage are in a comparable range. These findings, i.e., the remarkable cutting ability and the tolerable damage zone, clearly show that the diode laser is a very effective and, because of its excellent coagulation ability, useful alternative in soft-tissue surgery of the oral cavity.

REFERENCES

1. Liboon J, Funkhouser W, Terris D. Comparison of mucosal incisions made by scalpel, CO₂ laser, electrocautery and constant-voltage electrocautery. *Otolaryngol Head Neck Surg* 1997;116:379-385.
2. Wilder-Smith P, Arrastia AM, Liaw LH, Berns M. Incision properties and thermal effects of thoursee CO₂ lasers in soft tissue. *Oral Surg Oral Med Oral Pathol Oral Radiol Endod* 1995;79:685-691.
3. Wilder-Smith P, Dang J, Kurosaki T. Investigating the range of surgical effects on soft tissue produced by a carbon dioxide laser. *J Am Dent Assoc* 1997;128:583-588.
4. Pick RM, Colvard MD. Current status of lasers in soft tissue dental surgery. *J Periodontol* 1993;64:589-602.
5. Gold SI, Vilardi MA. Pulsed laser beam effects on gingiva. *J Clin Periodontol* 1994;21:391-396.
6. White JM, Goodis HE, Rose CL. Use of the pulsed Nd:YAG Laser for intraoral soft tissue surgery. *Lasers Surg Med* 1991;11:455-561.
7. Perry D, Goodis H, White J. In vitro study of the effects of Nd:YAG laser probe parameters on bovine oral soft tissue excision. *Lasers Surg Med* 1997;20:39-46.
8. Douglas N, Dederich NH. Laser/tissue interaction. *Alpha Omega* 1991;84:33-36.
9. Matin NH, Orikasa N, Kusakari H. Effects of CO₂ laser irradiation to periodontal tissues. *Int Soc Laser Dent* 1995; Abstracts 9.
10. Walsh JT Jr, Deutsch TF. Pulsed CO₂ laser tissue ablation. measurement of the ablation rate. *Lasers Surg Med* 1988;8:3:264-275.

11. White JM, Goodis HE, Yessic MJ, Meyers TD. Histologic effects of a high repetition pulsed Nd:YAG laser on oral soft tissue. In: Wigor HA, Featherstone JDB, White JM, eds. *Lasers in dentistry*. International Society for Optical Engineering. Proc SPIE 2394; 1995. p 129-141.
12. Moritz A, Schoop U, Goharkhay K, Wernisch J, Sperr W. Procedures for enamel and dentin conditioning: a comparison of conventional and innovative methods. *J Esthet Dent* 1998;10:84-93.
13. Moritz A, Schoop U, Goharkhay K, Doertbudak O, Sperr W. Rapid report: irradiation of infected root canals with a diode laser in vivo. *Lasers Surg Med* 1997;21:221-226.
14. Moritz A, Schoop U, Goharkhay K, Wernisch J, Sperr W. Treatment of periodontal pockets with a diode laser. *Lasers Surg Med* 1998;22:302-311.
15. Wilder-Smith P, Dang J, Kurosaki T, Neev J. The influence of laser parameter configurations at 9.3 microns on incisional and collateral effects in soft tissue. *Oral Surg Oral Med Oral Path Oral Radiol Endod* 1997;84:22-27.
16. Fitzpatrick RE, Ruiz-Esparza J, Goldman MP. The depth of thermal necrosis using the CO₂ laser: a comparison of the superpulsed mode and conventional mode. *J Dermatol Surg Oncol* 1991;17:340-344.
17. Bar-Am A, Lessing JB, Niv J, Brenner SH, Peyser MR. High and low-power CO₂ lasers. Comparison of results for three clinical indications. *J Reprod Med* 1993;38:455-458.
18. Nelson JS, Berns MW. Basic laser physics and tissue interactions. *Contemp Dermatol* 1988;2:3-15.
19. Luciano AA, Frishman GN, Maier DB. A comparative analysis of adhesion reduction, tissue effects, and incising characteristics of electrosurgery, CO₂ laser, and Nd:YAG laser at operative laparoscopy: an animal study. *Laparoendoscopic Surg* 1992;2:287-292.
20. Scherer H, Fuhrer A, Hopf J. Current status of laser surgery of benign diseases in the area of the soft palate. *Laryngol Rhinol Otol* 1994;73:14-20.
21. Zweig AD, Meierhofer B, Muller OM. Lateral thermal damage along pulsed laser incisions. *Laser Surg Med* 1990;10:262-274.
22. McKenzie AL. A thoursee-zone model of soft-tissue damage by a CO₂ laser. *Phys Med Biol* 1986;31:967-983.
23. Polanyi TG. Laser physics: medical applications. *Otolaryngol Clin North Am* 1983;16:753-774.
24. Wyman A, Duffy S, Sweetland HM, Sharp F, Rogers K. Preliminary evaluation of a new high power diode laser. *Lasers Surg Med* 1992;12:506-509.
25. Judy MM, Matthews L, Aronoff B, Hulst D. Soft tissue studies with 805 nm diode laser radiation: thermal effects with contact tips and comparison with effects of 1064 nm Nd:YAG laser radiation. *Lasers Surg Med* 1993;13:528-536.
26. Schoursoder T, Brackett K, Joffe S. An experimental study of the effects of electrocautery and various lasers on gastrointestinal tissue. *Surgery* 1987;101:691-697.
27. Rastegar S, Motamedi M, Jacques SL, Kim MB. Theoretical analysis of equivalency of high-power diode laser (810 nm) and Nd:YAG laser (1064 nm) for coagulation of tissue. Predictions for prostate coagulation. [Proceedings of the Laser-Tissue Interaction III. 21-24 Jan (1992). Los Angeles] Washington, Soc of Photo-Optical Instrumentation Engineers.
28. Goldman L, Shumrick DA, Rockwell RJ, Meyer R. The laser in maxillofacial surgery. *Arch Surg* 1968;96:397-400.
29. Clayman L, Fuller T, Beckman H. Healing of continuous-wave and rapid superpulsed, carbon dioxide, laser induced bone defects. *J Oral Surg* 1978;36:932-937.
30. Niemz M. *Laser tissue interactions*. Springer, Berlin; 1996. p 69.